

SHOULDER

ULTRASOUND

ANTERIOR & ANTERIOR-LATERAL

Anterior Shoulder

Structure Seen: Long Head of Biceps Tendon
Subscapularis

Arm Positioning: Elbow Flexed at 90 degrees
For Subscapularis: forearm externally rotated

Dynamic Evaluation: Internal & external rotation with the elbow bent at 90 degrees

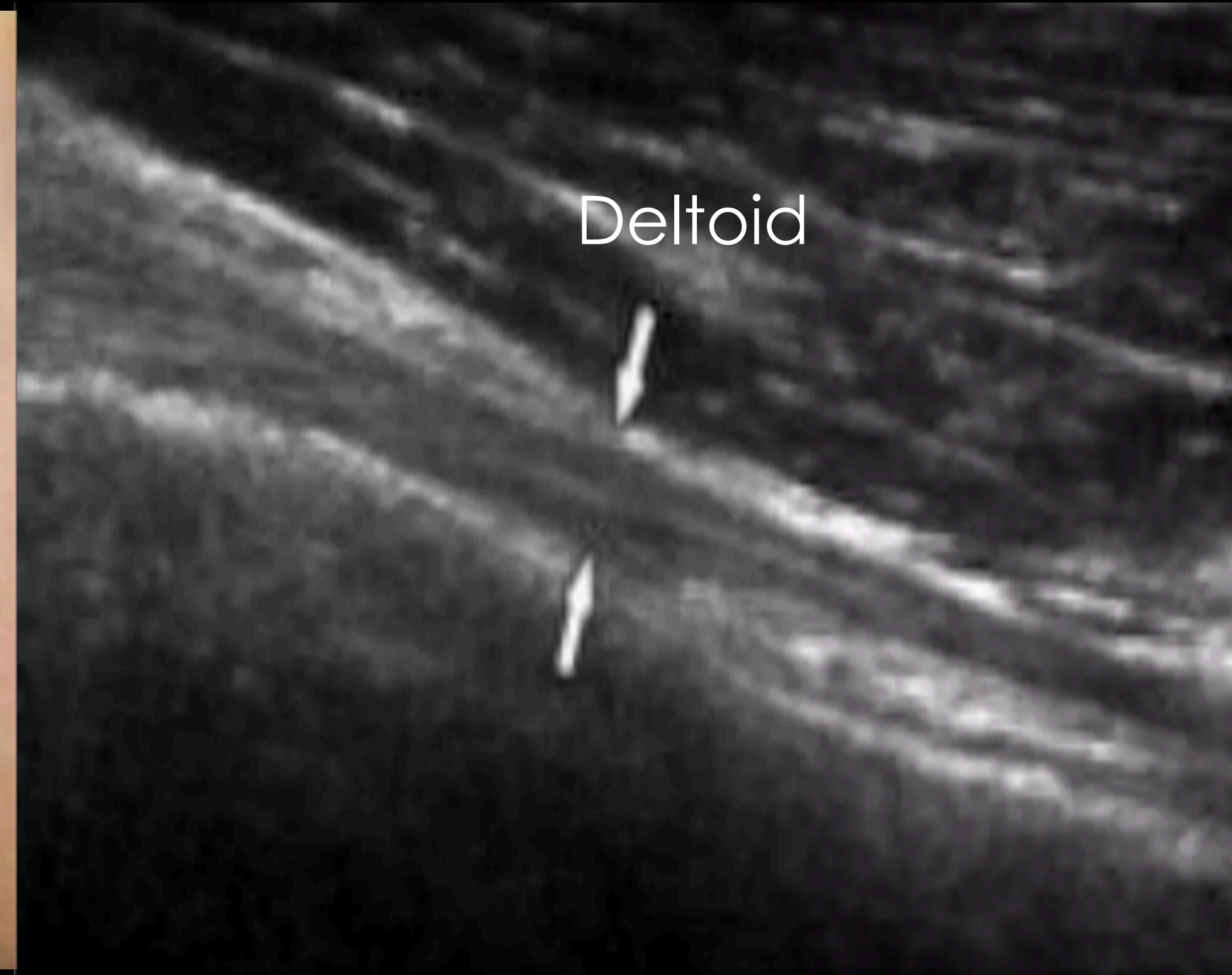
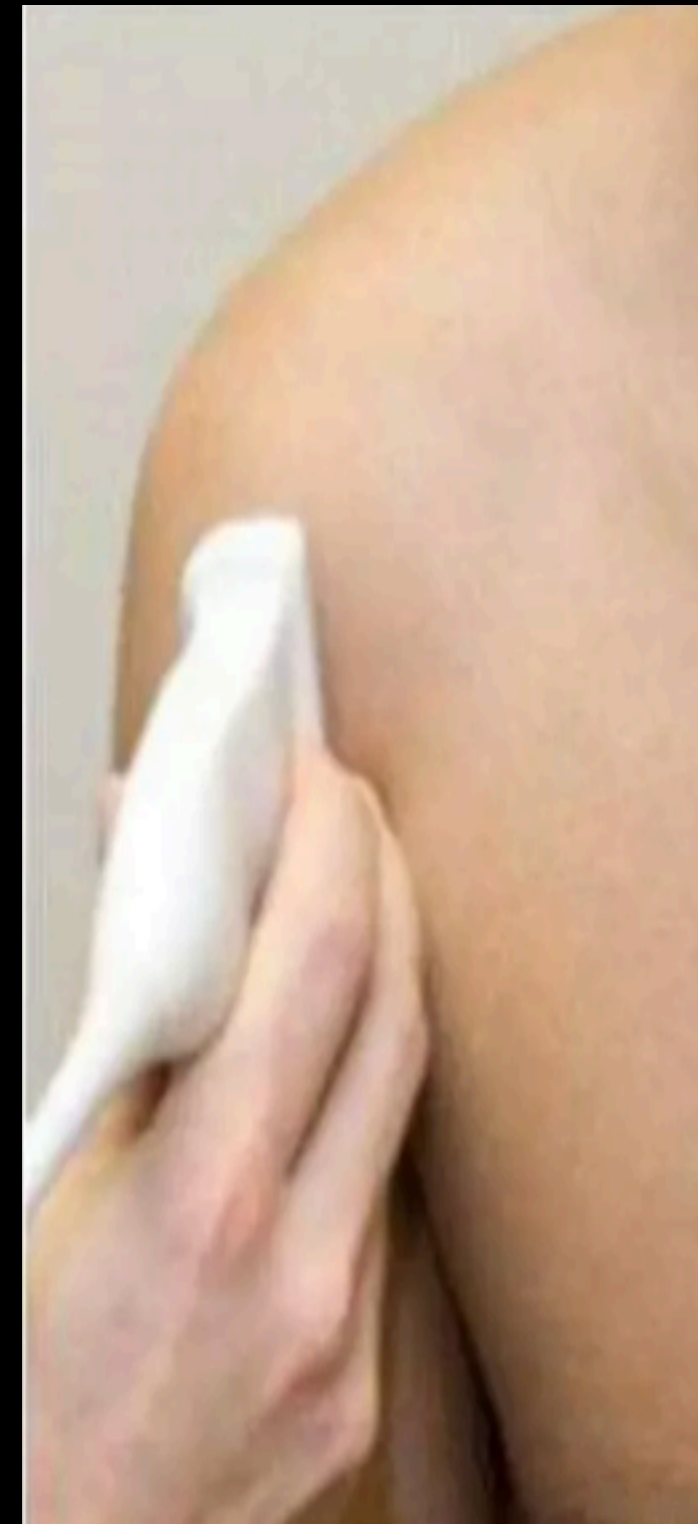
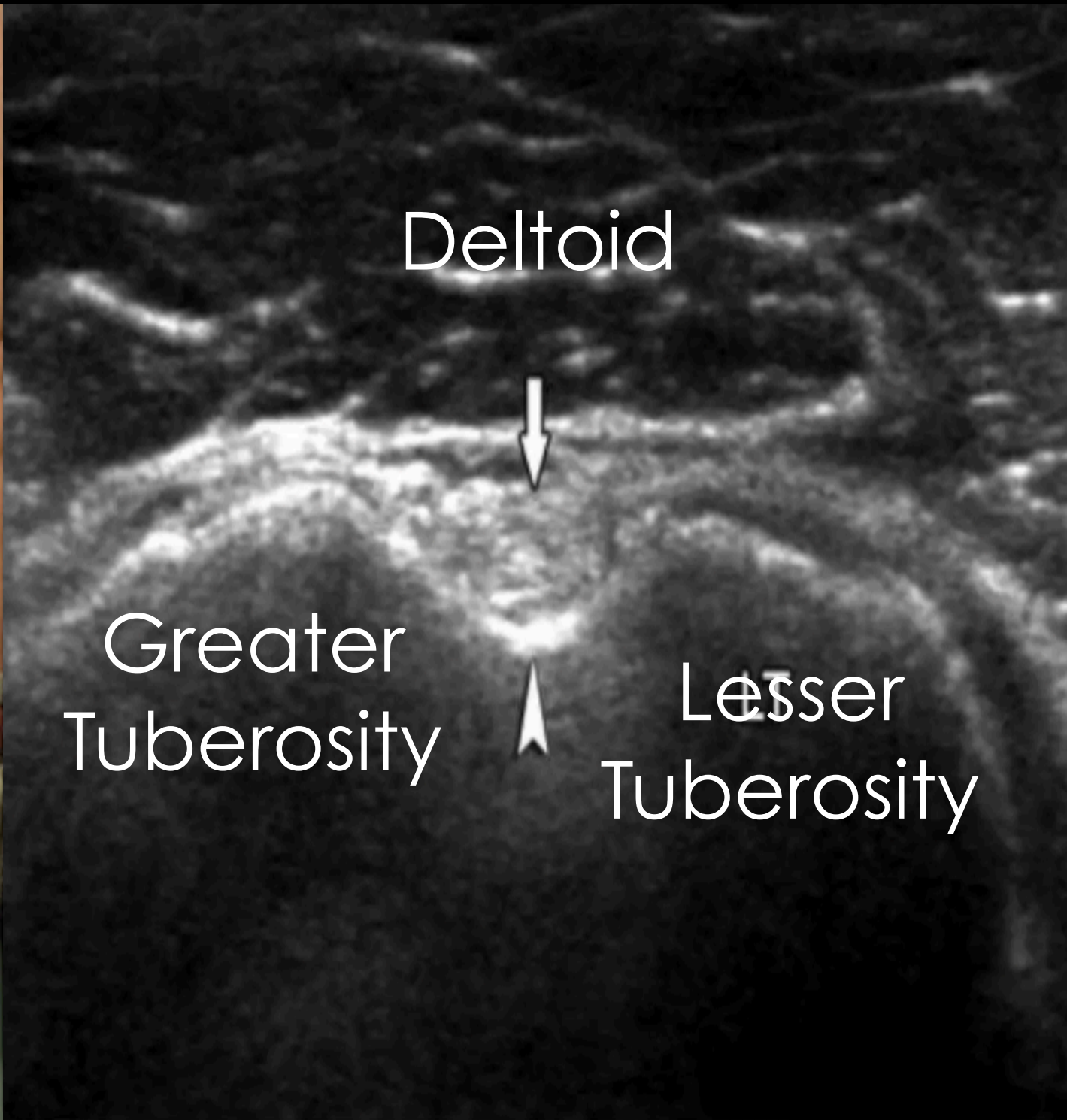
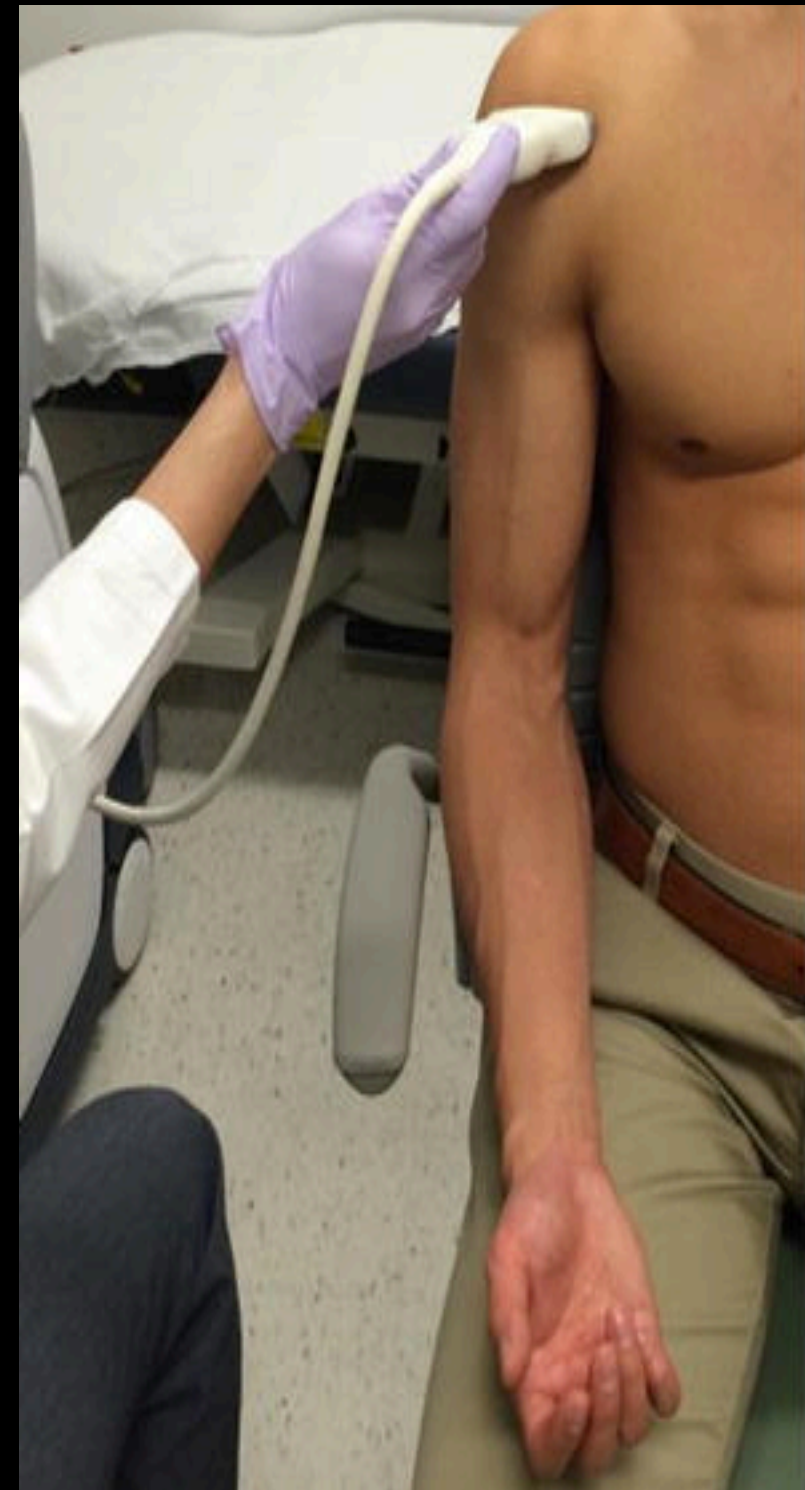Anterior Lateral Shoulder

Supraspinatous
& Subacromial-subdeltoid bursa

Internal Rotation

Have the patient abduct the arm away (checking for supraspinatous impingement)


Long Head Biceps Tendon



TRANSVERSE

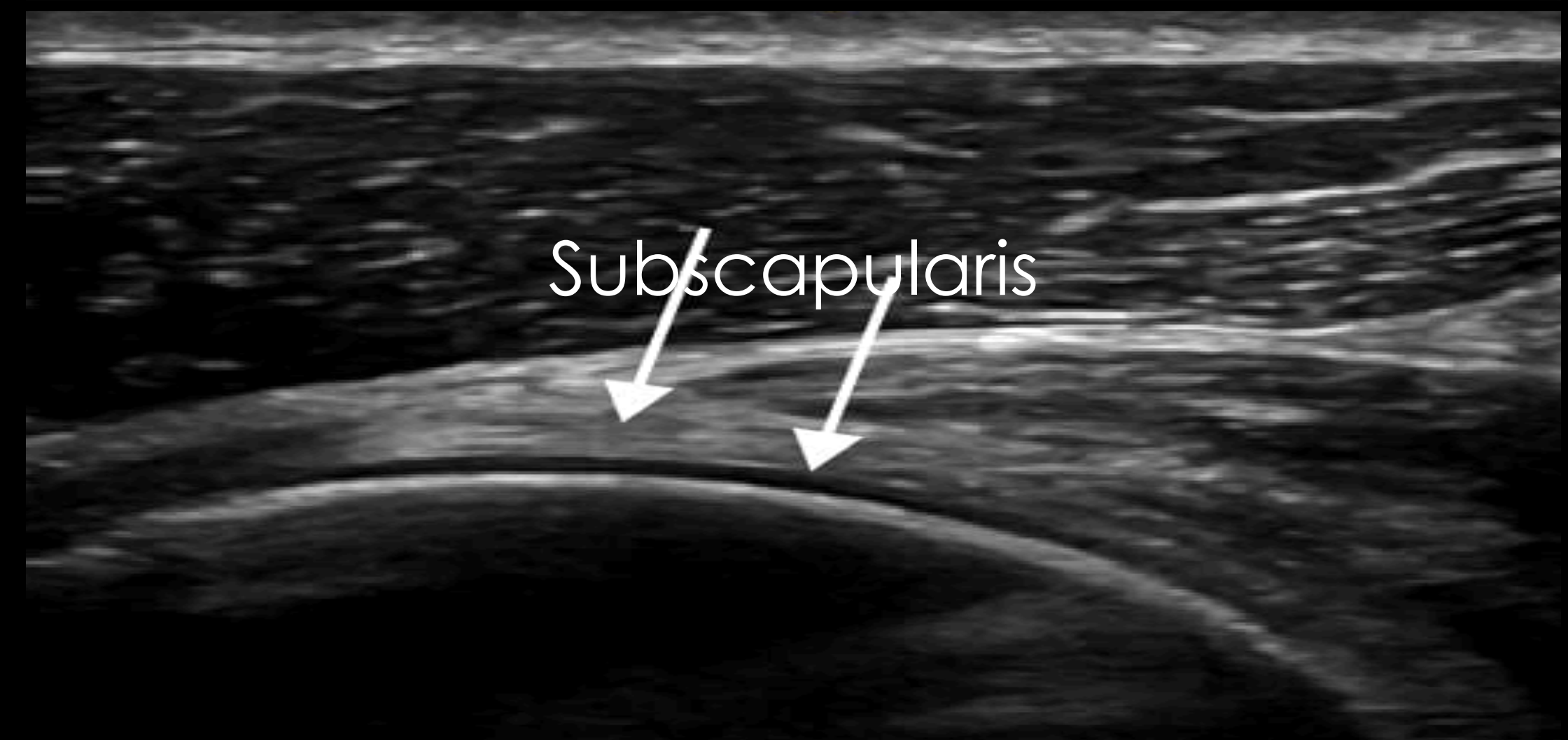
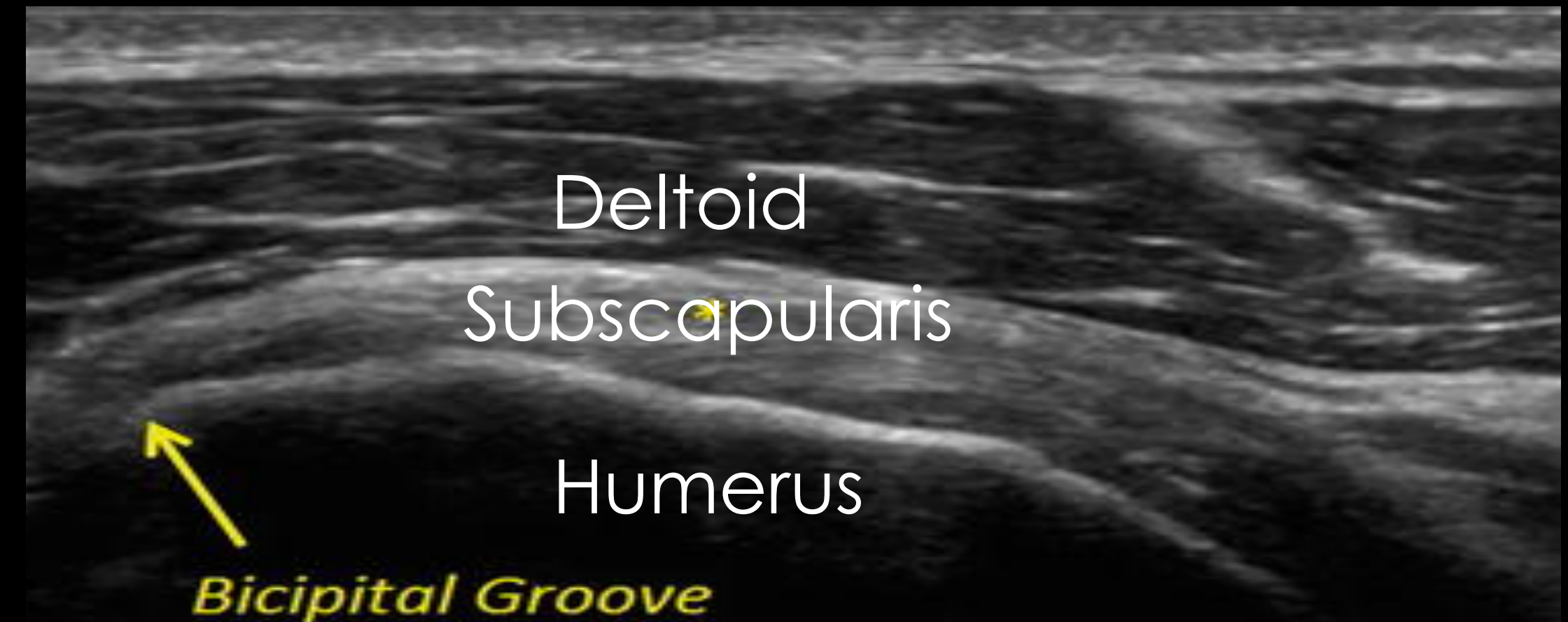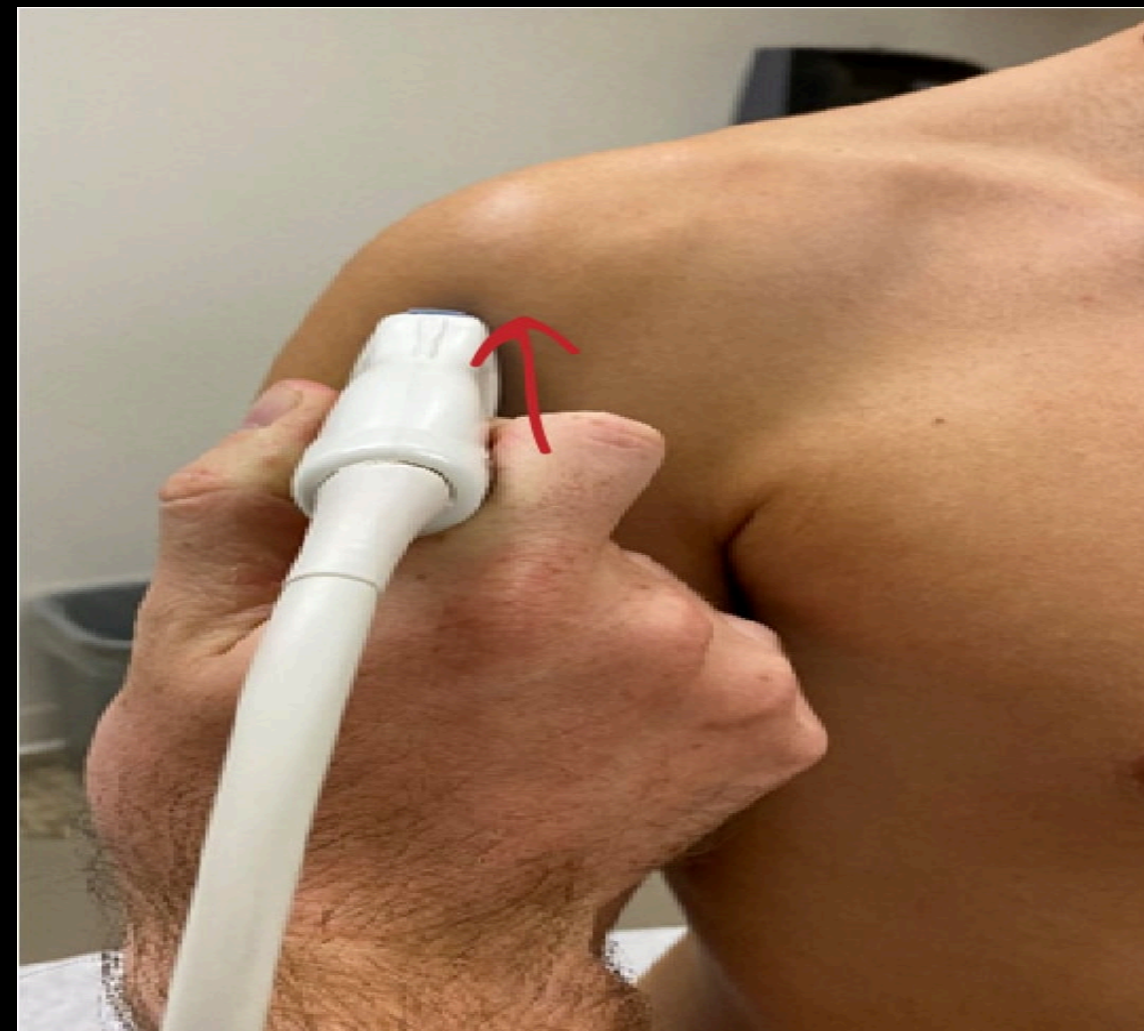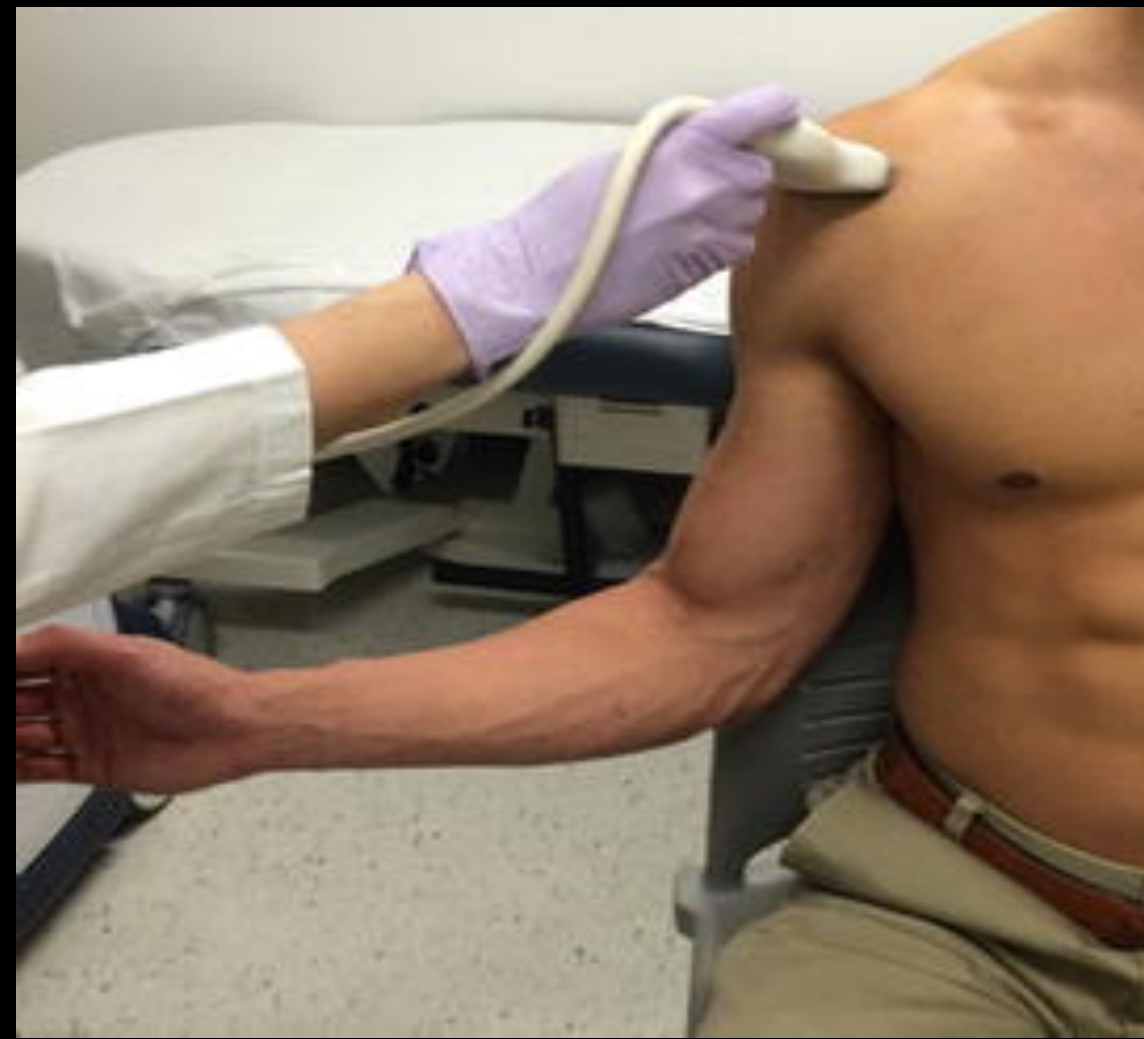SAGITAL

Subscapularis

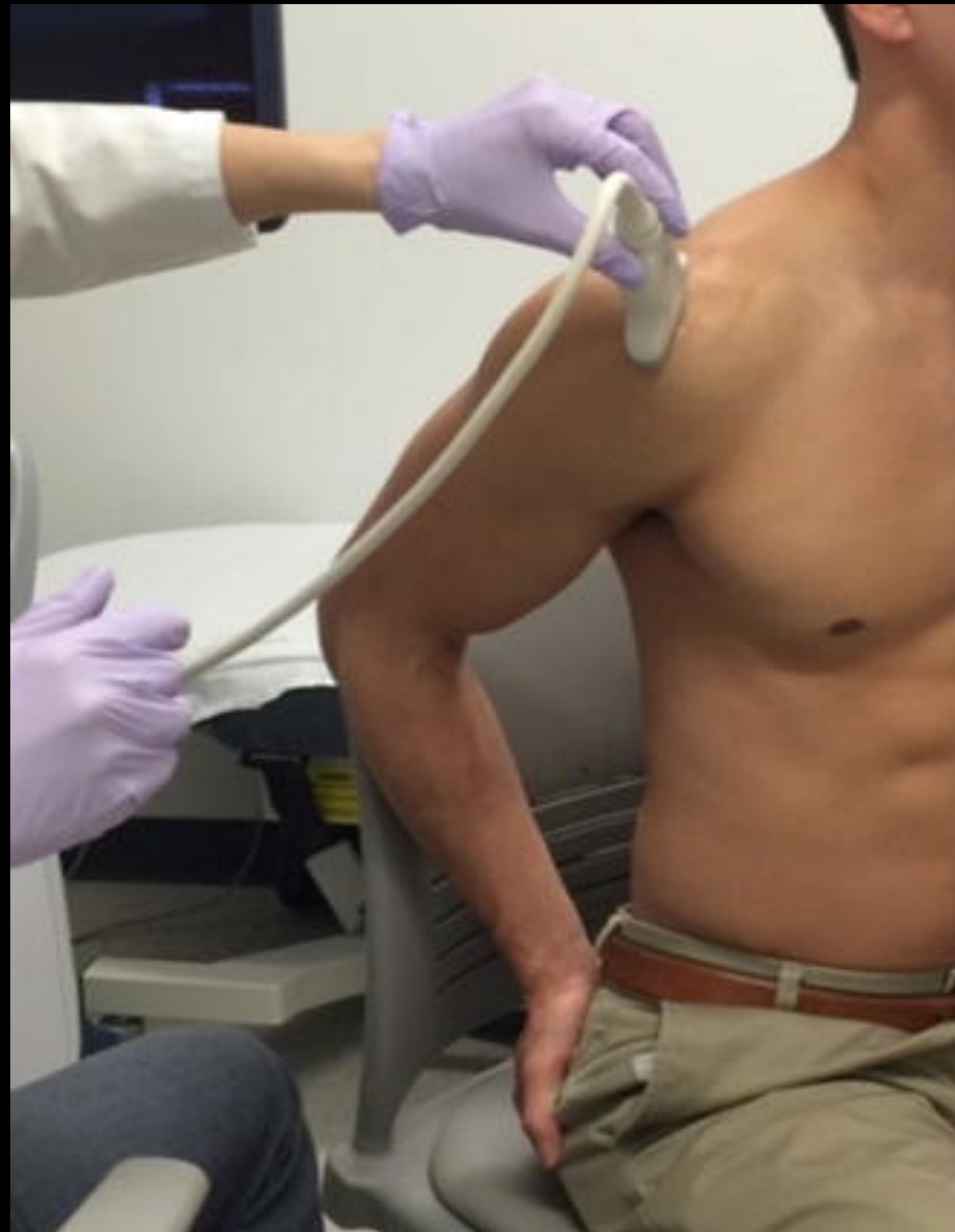

To evaluate the subscapularis:

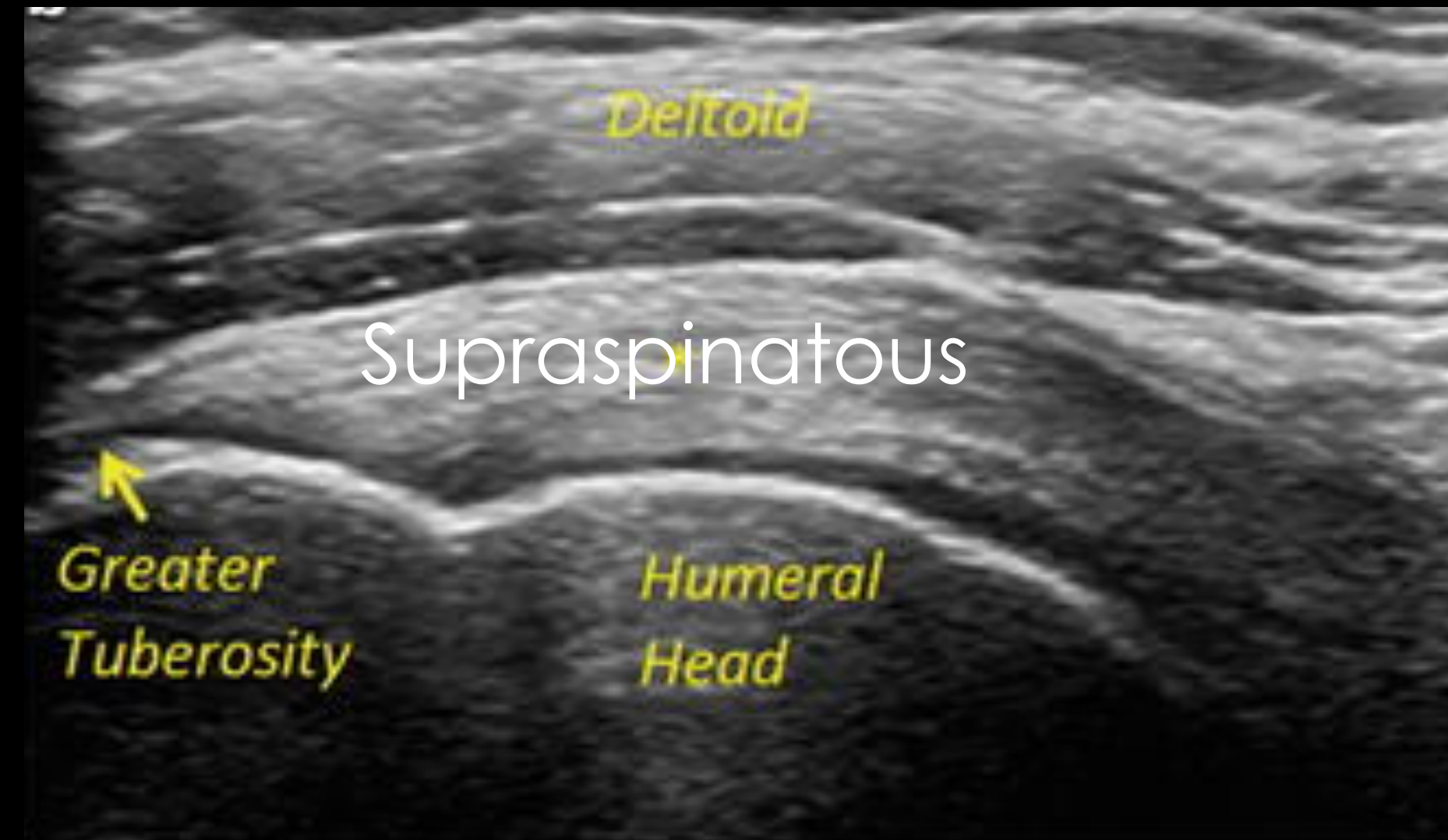From your transverse biceps view, leave the probe stationary and externally rotate the arm. The subscapularis comes into view.



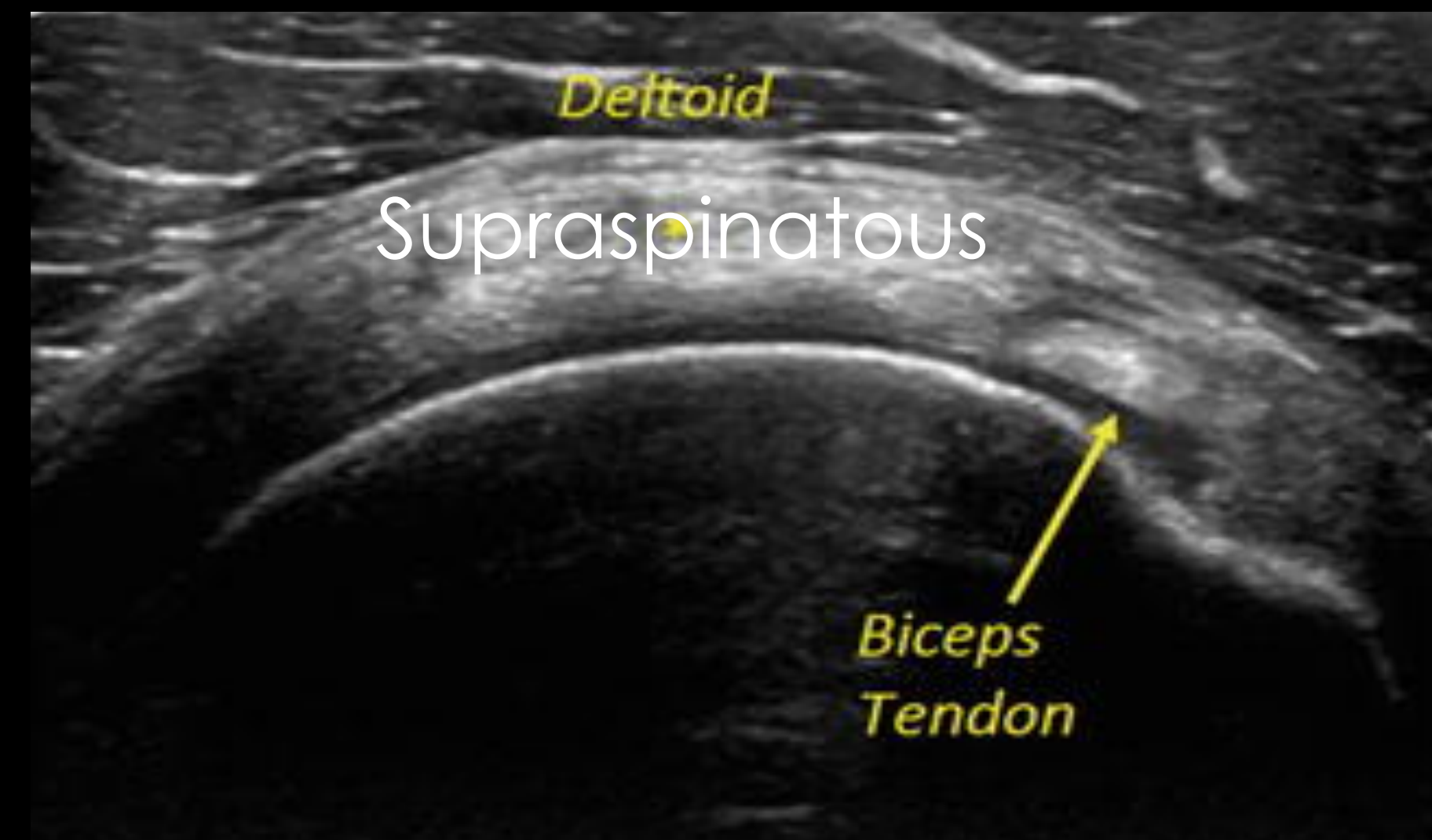
Supraspinatous



SAGITAL

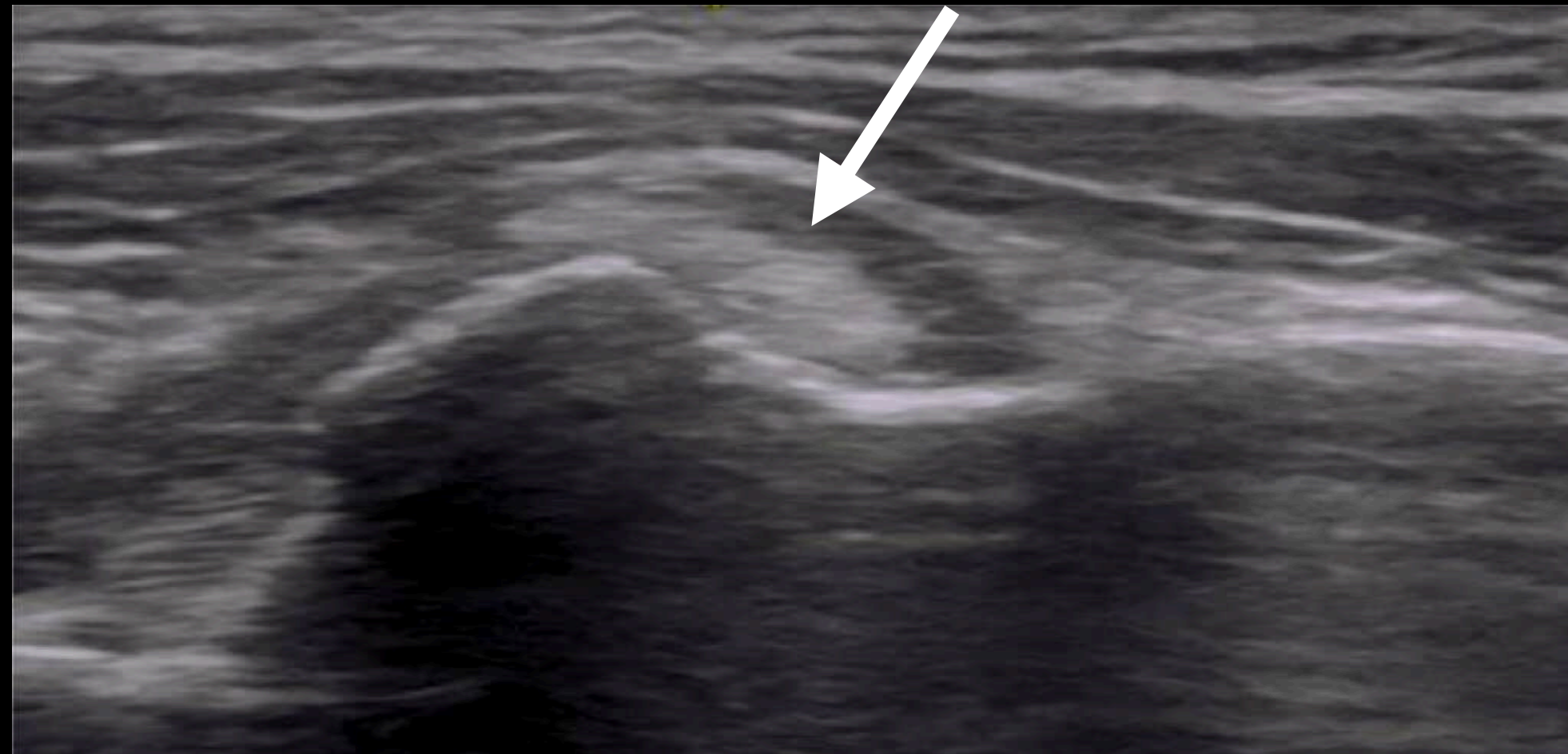


TRANSVERSE

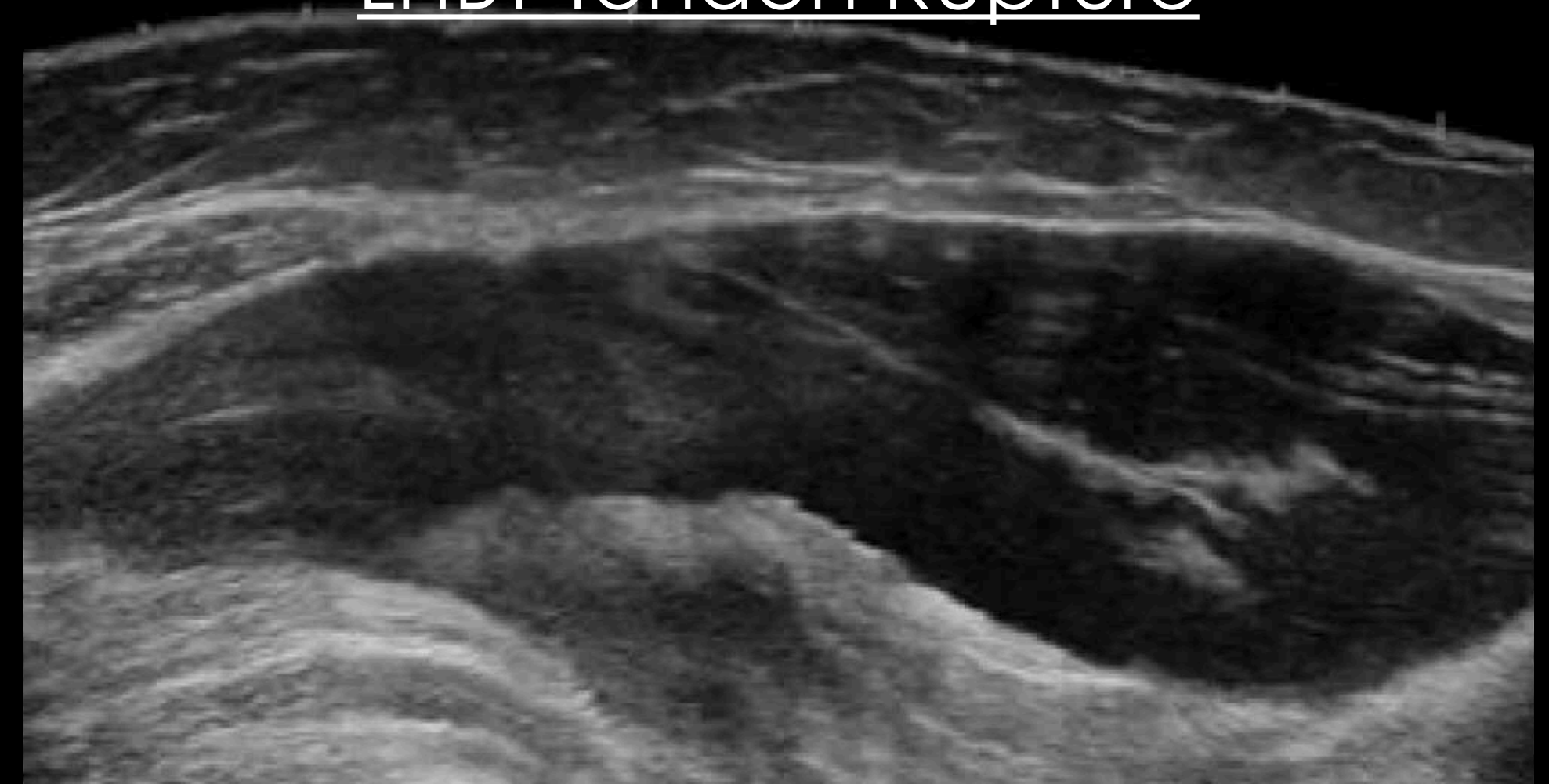


Long Head Biceps Tendon (LHBT) Pathology

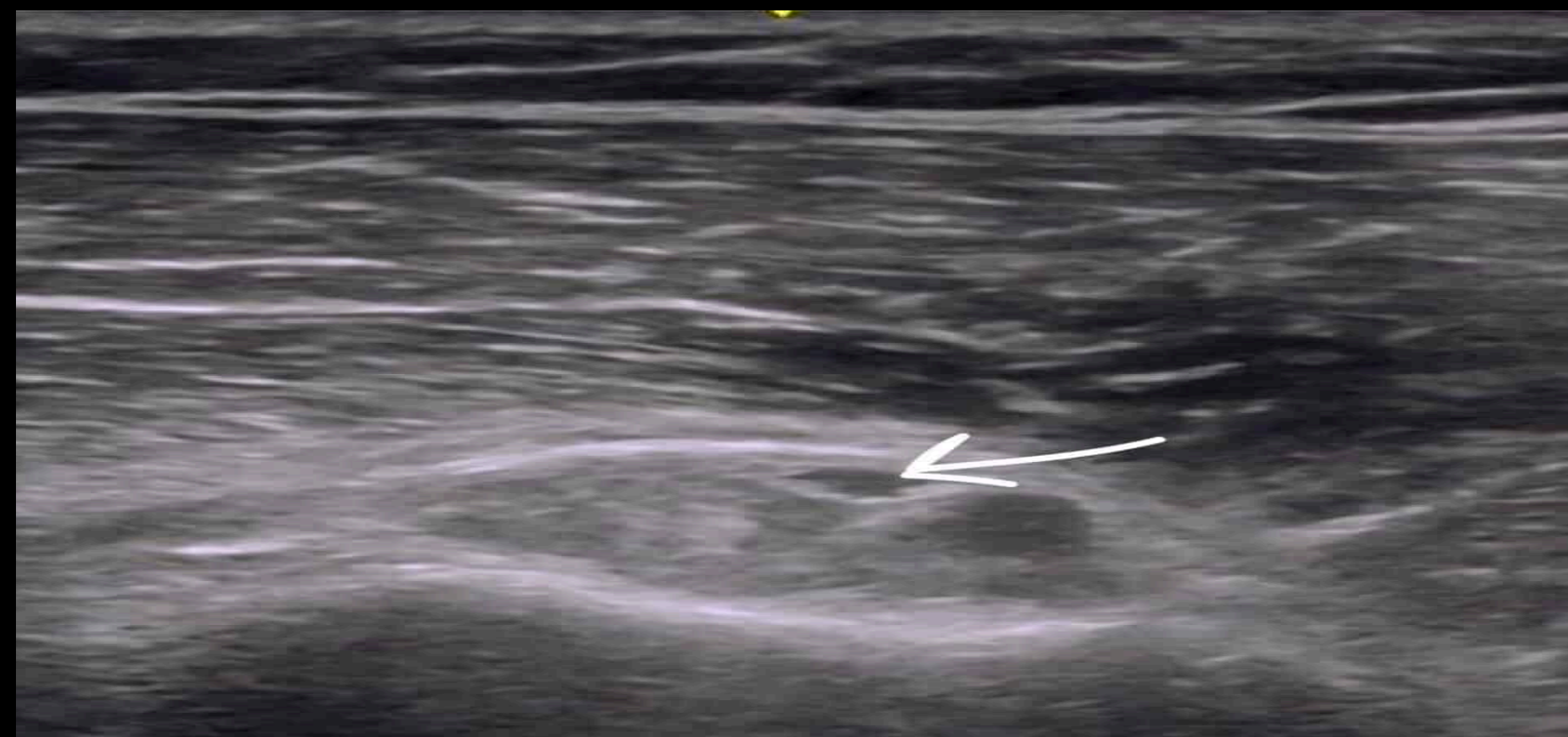LHBT Subluxation



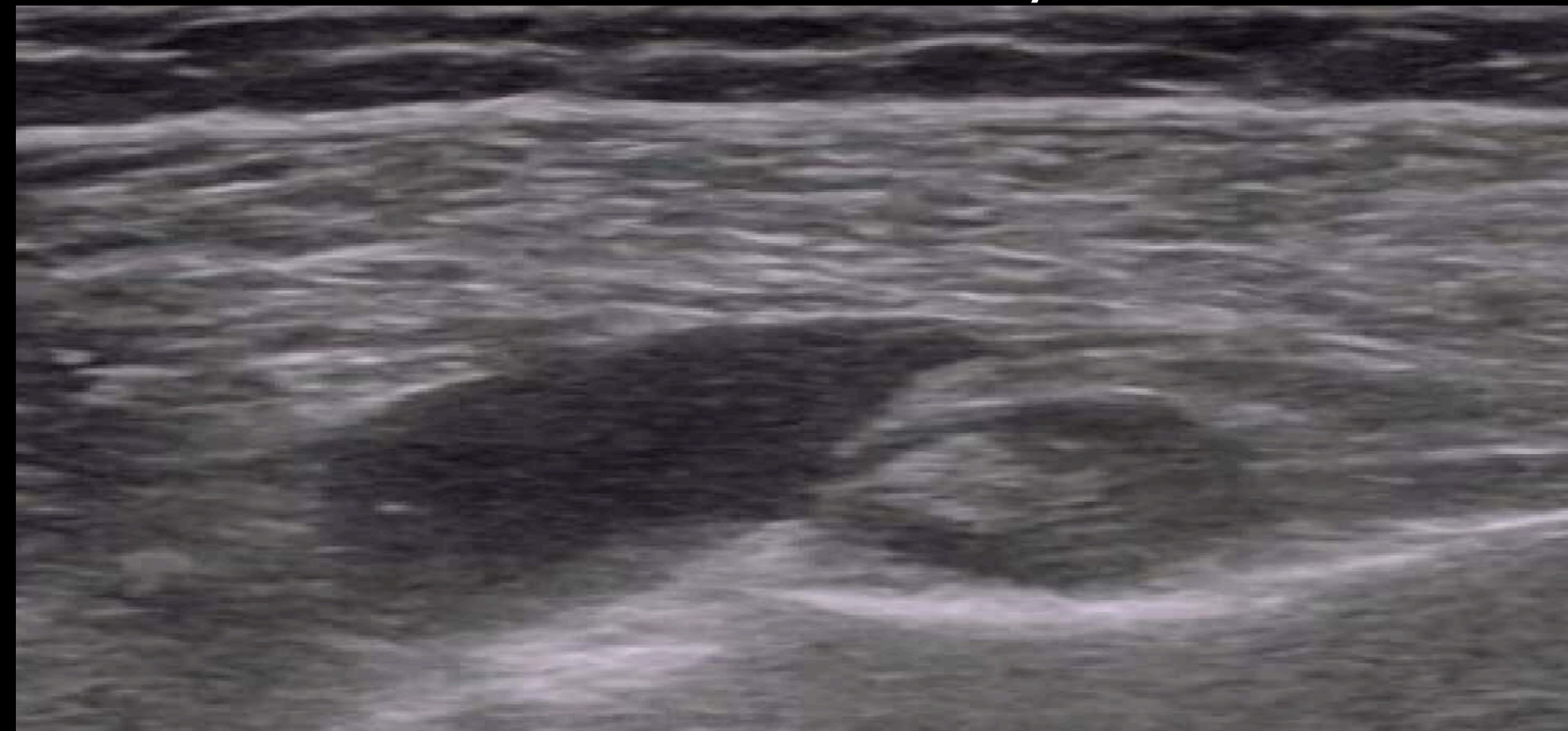
LHBT Tendon Rupture



LHBT Tendonitis

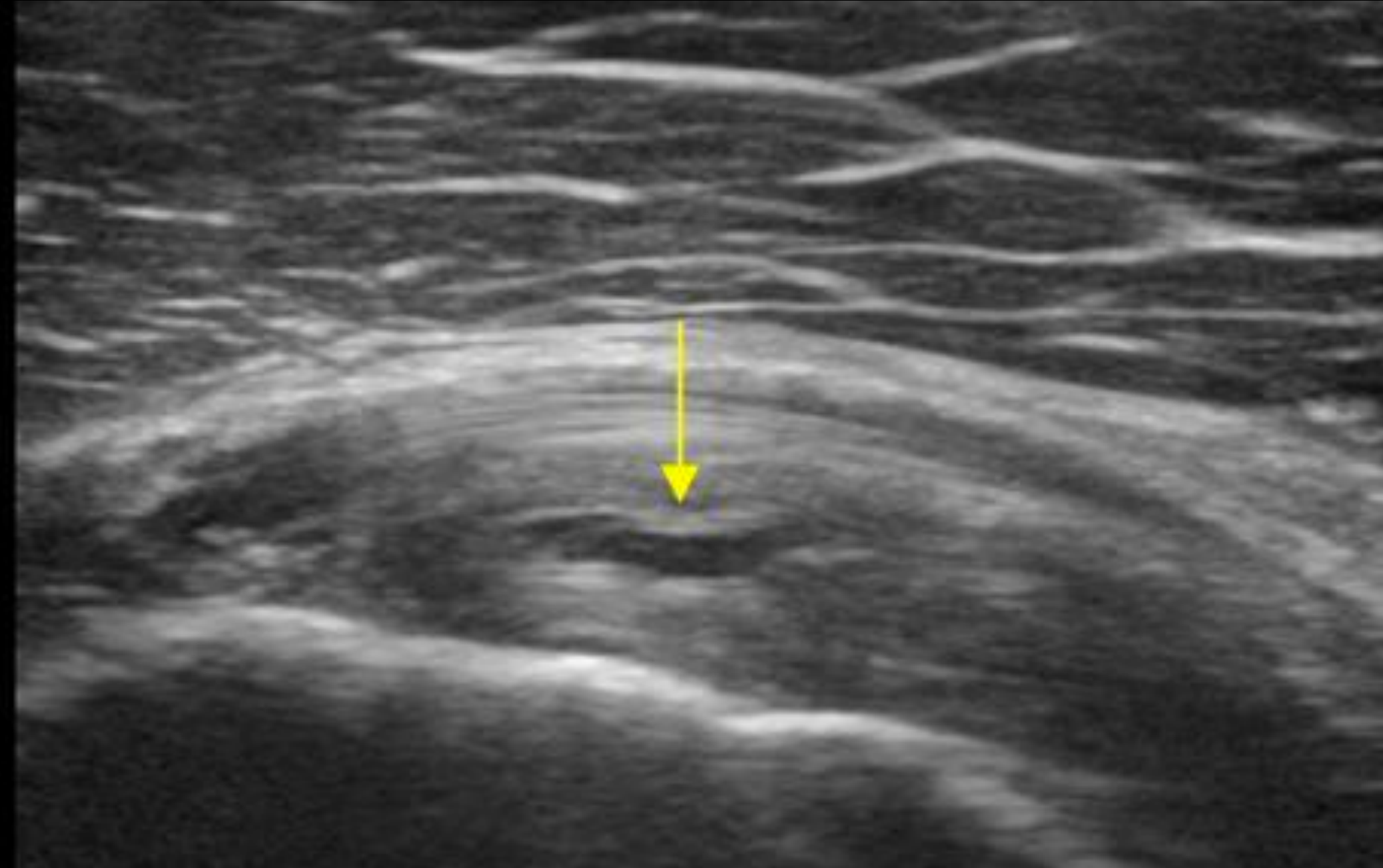


LHBT Tendon Tenosynovitis



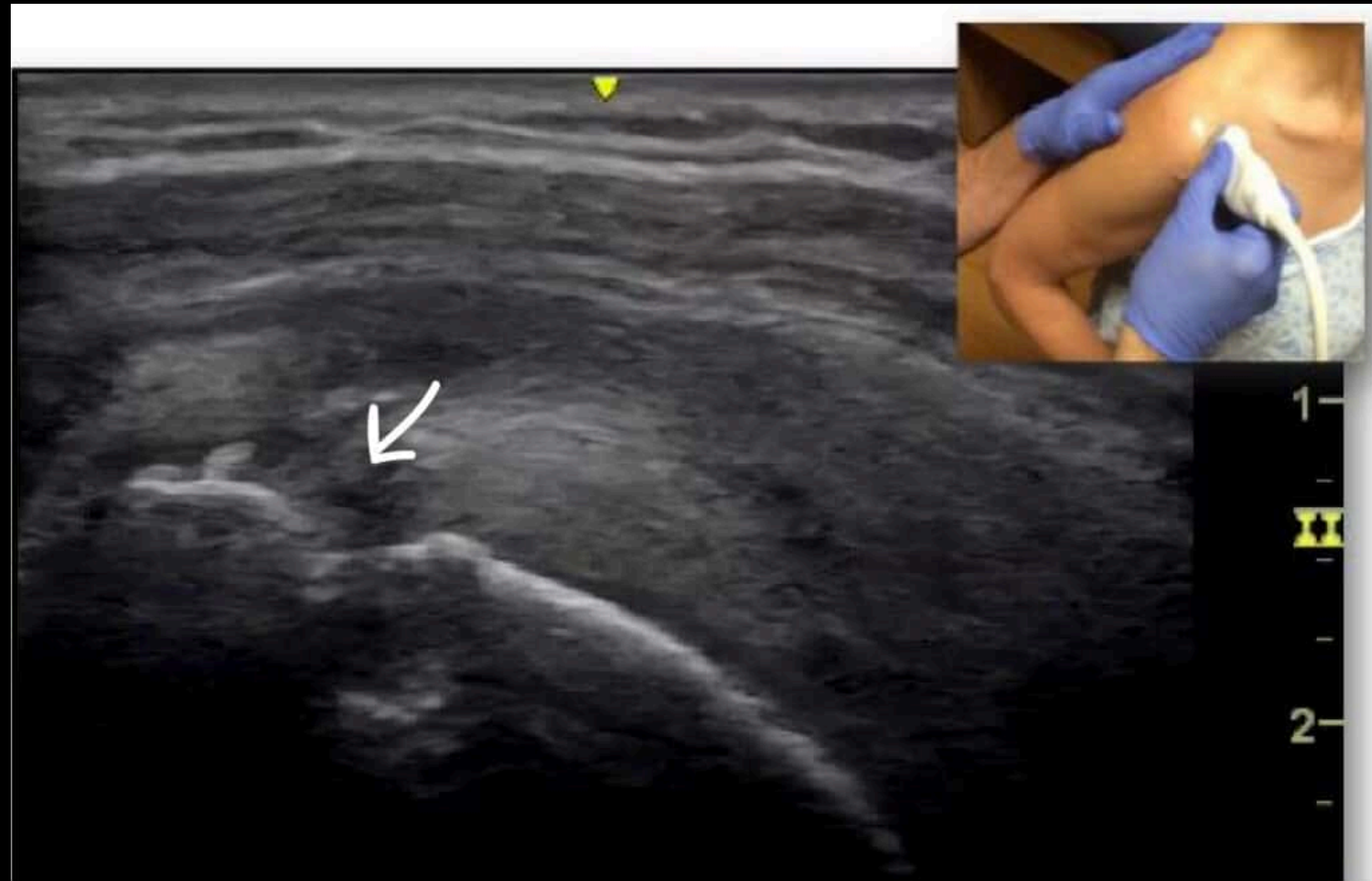
Subscapularis Pathology

Subscapularis Tear



Supraspinatous Pathology

Supraspinatous Impingement



Supraspinatous Tear

